Region Örebro County
Örebro University Hospital

Special cases where SGRT is extra helpful

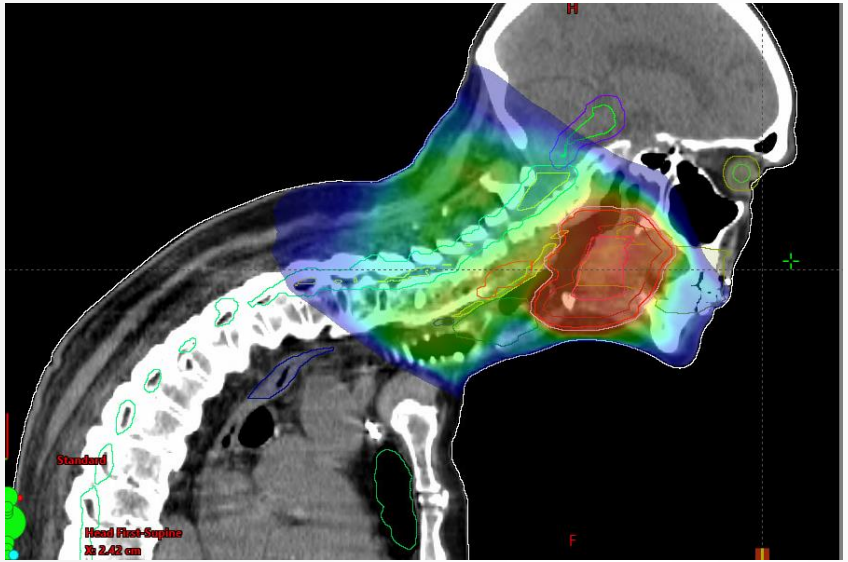

Ulf Granlund, Medical Physicist

(Jessica Waldesjö, Oncology Nurse)

Region Örebro County
Örebro University Hospital

Radiotherapy department Örebro - Equipment

- 1 Siemens go.Open Pro* → Vision RT – Sim RT with visual guide
- 3 True Beam w 6 DoF couch → Vision RT - Align RT with Postural Video
- OIS Aria → 2 extra VRT workstations
- TPS Eclipse

* CT is currently under installation



Region Örebro County
Örebro University Hospital

Radiotherapy department Örebro – Vision RT timeline

May 2015: First installation on 2 linacs + CT.

Feb 2016: First DIBH treatment.

2017-2018: Align RT replaces kV-images on breast w/o nodes.

2019: Align RT also on our third linac. We stop using tatoos on breast.

2021: Postural Video, initially on evaluation, from late 2022 on permanent license.

April 2022: Upgrade to new verision with new GUI. Due to this, and Postural Video, we use Align RT on essentially all patient groups. We stop using tatoos on all except SBRT and a few pall.

April 2023: Upgrade to Sim RT with Visual Guide on CT.

2023: ”Beamhold ON” in use on almost all patient groups.

Region Örebro County
Örebro University Hospital

Radiotherapy department Örebro – Patients 2023

- H&N: 90
- Breast (dx/sin): 183
- Prostate: 272
- Gynecological: 23
- Gastrointestinal 65
- Thorax 33
- Gynecological 33
- Genitourinary 21
- Others: 344

Totalt 2023: 1062*



* Numbers are unique patient ID:s. Some had more than one treatment course.

Region Örebro County
Örebro University Hospital

Special cases where SGRT is extra helpful

Case 1:

83 year old male

Diagnosis: Base of tongue cancer

Prescribed dose: 2 Gy x 34 to primary, 1.6 Gy x 34 to Lgl (SIB)

Treated 230314 - 230428

The patient has given written consent to presentation of images from the treatment.

Region Örebro County
Örebro University Hospital

Case 1 challenge nr 1. Anatomy:



Very difficult to make a stable mask fixation for this anatomy!

Region Örebro County
Örebro University Hospital

Case 1 Solution nr 1: Treatment setup

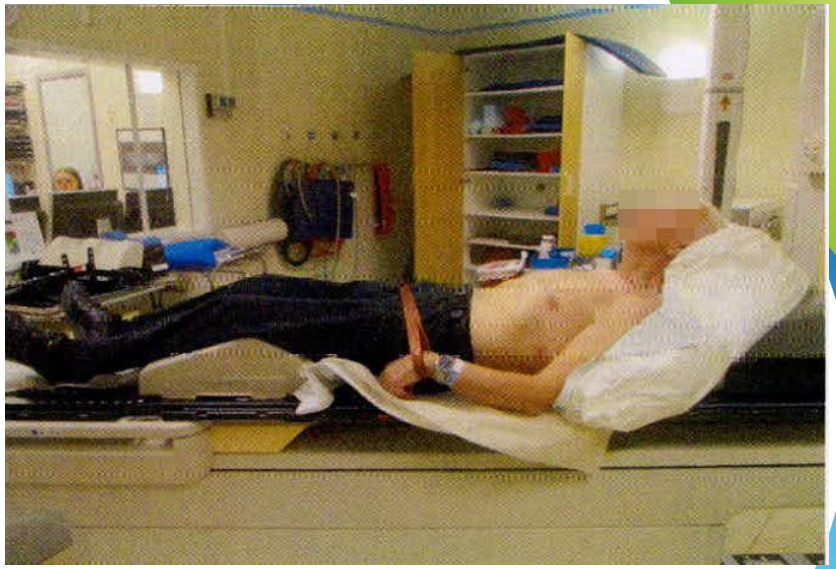

Vacuum bag with knee fix.

Region Örebro County
Örebro University Hospital

Case 1 challenge nr 2. Dose distribution:

This geometry is not ideal for a standard VMAT plan. We get unwanted dose to nose, sinuses and eyes. We can’t avoid beam entry through these organs to reach the target.

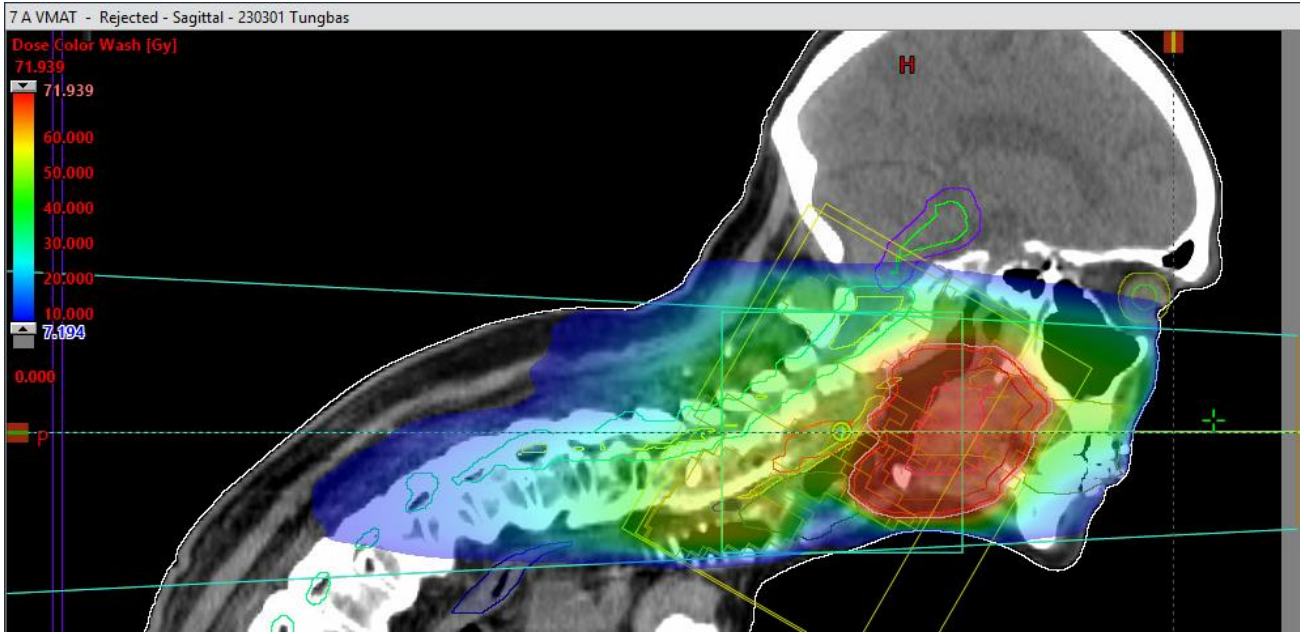

Region Örebro County
Örebro University Hospital

Case 1 solution nr 2: Treatment plan

IMRT plan with 7 fields, all with different gantry and couch angles.

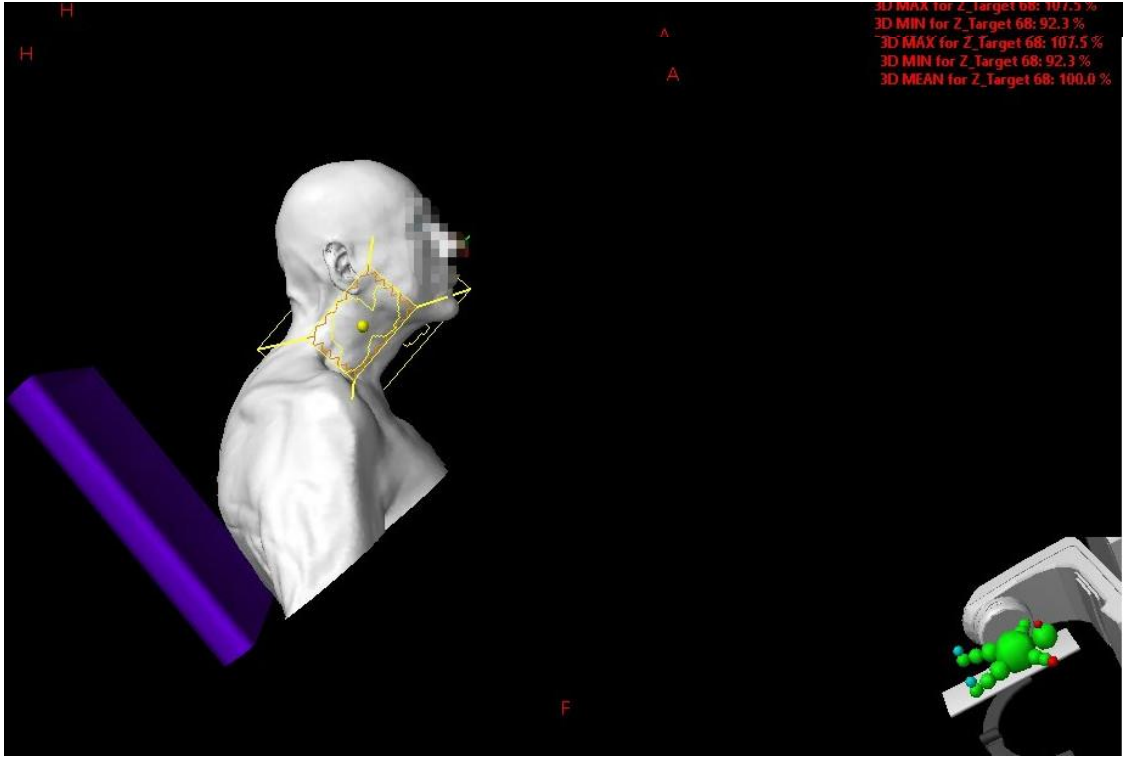

Region Örebro County
Örebro University Hospital

Case 1 solution nr 2: Treatment plan

IMRT plan with 7 fields, all with different gantry and couch angles.
Much less dose to nose, sinuses and eyes.

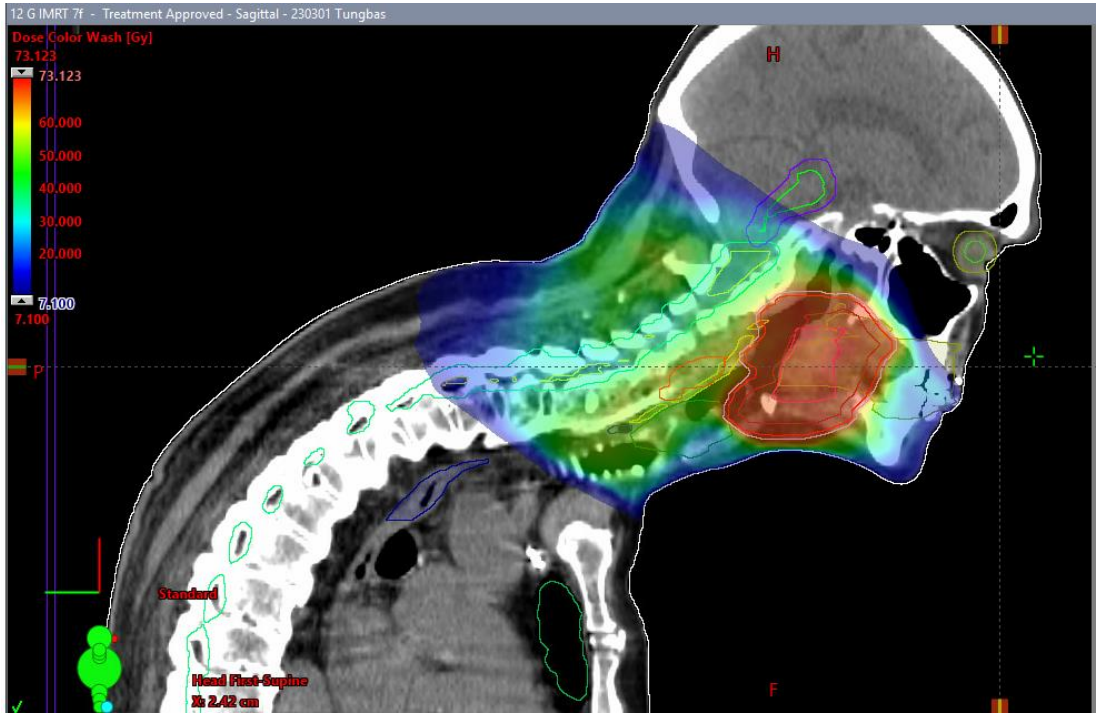

Region Örebro County
Örebro University Hospital

Case 1 challenge nr 3: Treatment accuracy

We now have a complex geometry treatment plan with 7 different couch angles. Can we reliably treat it with the below fixation setup !?

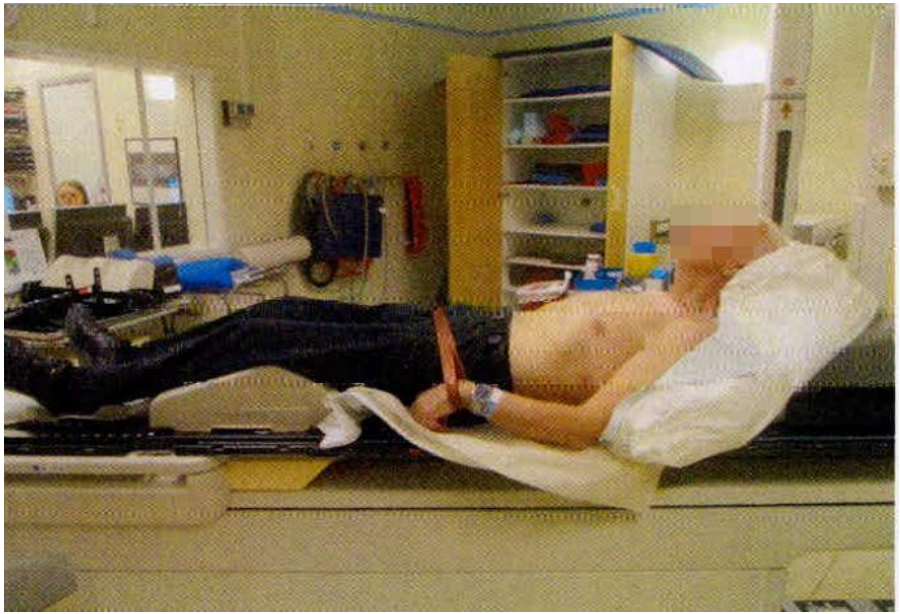

Region Örebro County
Örebro University Hospital

Case 1 challenge nr 3: Treatment accuracy

Hopefully AlignRT can help us with this treatment! We used the below ROI and settings.

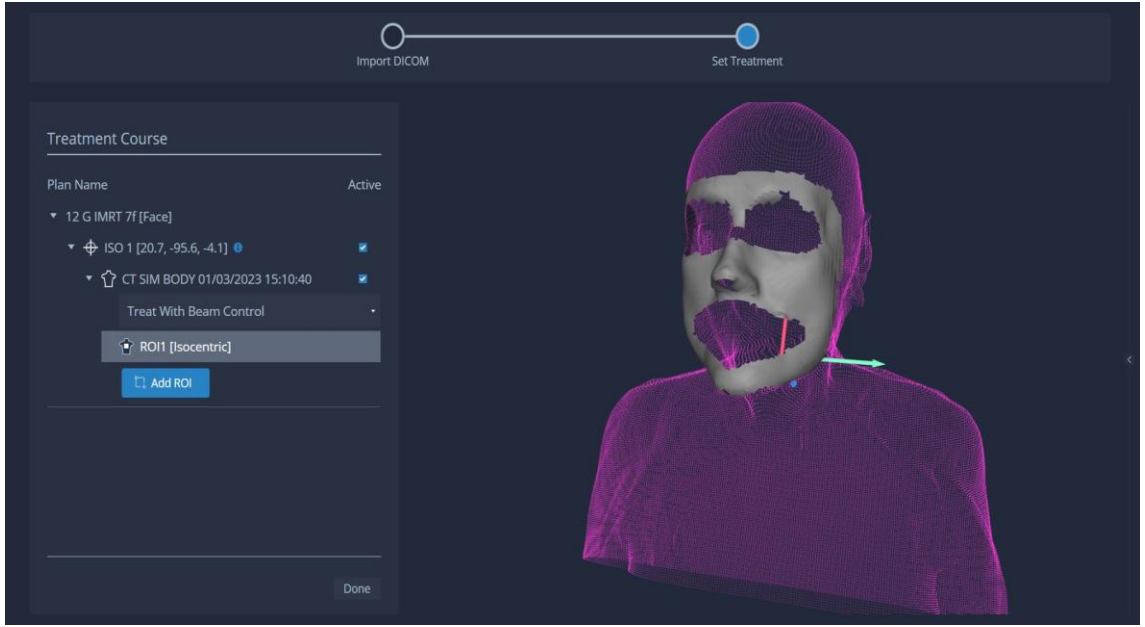

Region Örebro County
Örebro University Hospital

Case 1 challenge nr 3: Treatment accuracy

This was the initial setup in the treatment room, as seen by one AlignRT camera. Some extra support with tape on the forehead.

Region Örebro County
Örebro University Hospital

Case 1 challenge nr 3: Treatment accuracy

After a few treatment days, when the patient was more relaxed, AlignRT showed some pitch occurring during the treatment session. Extra kV imaging after treatment was done.

kV image before treatment.

kV image after treatment.

Region Örebro County
Örebro University Hospital

Case 1 challenge nr 3: Treatment accuracy

As both AlignRT and extra kV imaging showed, the patient was “dropping his chin” during treatment. Some extra support to the chin was added.

Case 1 Conclusions

- The use of AlignRT with motion monitoring gave us confidence to treat the patient with a complex and time consuming treatment plan.
- AlignRT indicated some issues during the treatment, which could be solved.
- The Postural Video was helpful in positioning the patient.
- The patient was comfortable with the treatment and the setup used. Even to the extent that he “fell asleep” sometimes.
- For the treatment staff it feels safe to use “Treat with Beam Control” when the patient is not so strongly fixated.

Region Örebro County
Örebro University Hospital

Special cases where SGRT is extra helpful

Case 2:

71 year old male

Diagnosis: Squamous cell carcinoma of the skin, scalp.

Multiple times surgery before radiotherapy.

Prescribed treatment: postoperative 2 Gy x 30.

Treated 230103 - 230217

The patient has given written consent to presentation of images from the treatment.

Region Örebro County
Örebro University Hospital

Case 2 Treatment setup

This patient setup was made with the intention to treat the patient with electrons. Focus was entirely on making the treatment area accessible for electron treatment.

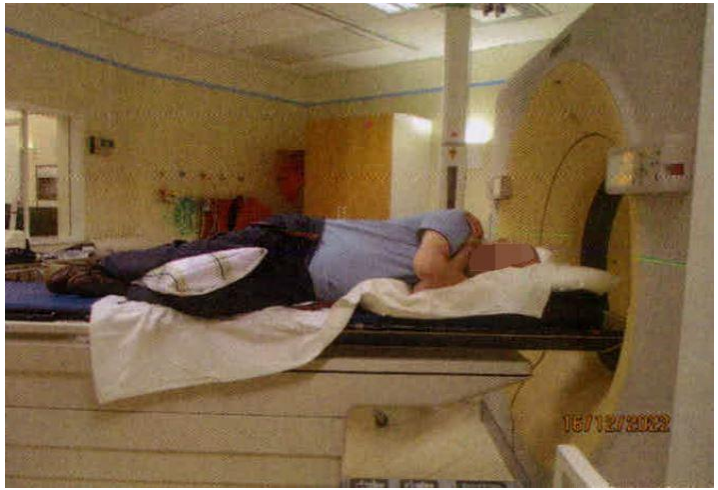

Reference point

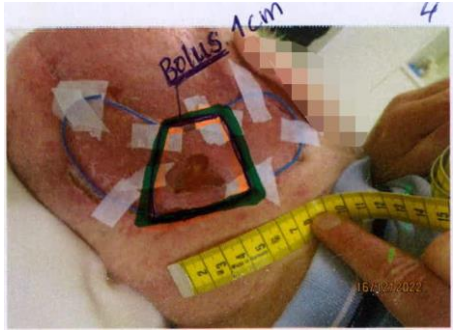

Bolus area

Region Örebro County
Örebro University Hospital

Case 2 Treatment setup

However: When the target delineation was made, the depth of the target depth including bolus was out of reach for our electron energies.

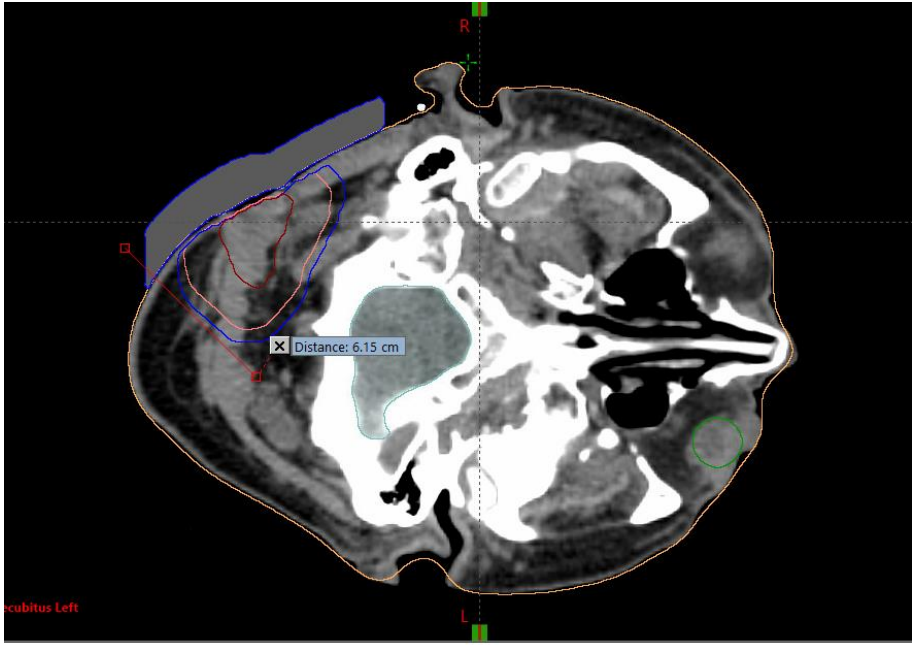

Region Örebro County
Örebro University Hospital

Case 2 Treatment plan

So now we had a patient with electron setup and a photon target. What to do? We decided to treat with photons anyway to avoid treatment delay. Normally a photon patient would have a setup with supine position and a fixation mask.

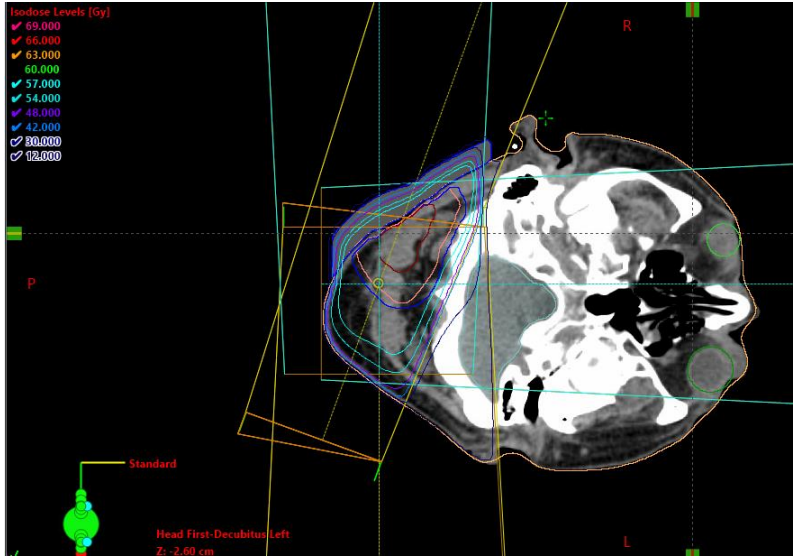

Region Örebro County
Örebro University Hospital

Case 2 Treatment

We used AlignRT with the ROI below to position and monitor the patient with good results.

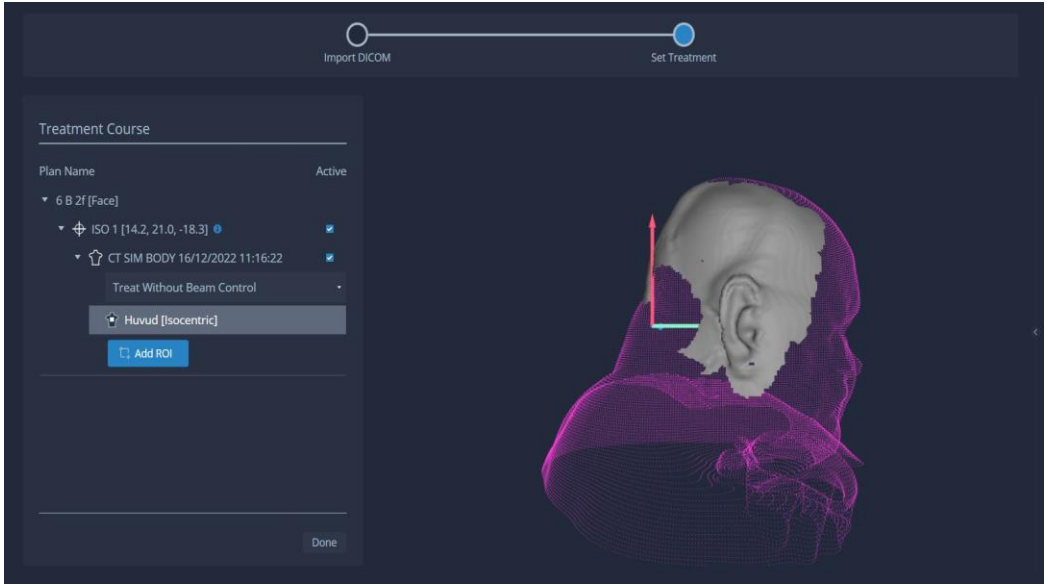

Region Örebro County
Örebro University Hospital

Case 2 Treatment

Postural video was helpful in aligning the patient. In particular it was important to position and align the patients back correctly in the vacuum bag.

Case 2 Conclusions

- The use of AlignRT with motion monitoring made it feasible to treat the patient with a different setup than we would normally have used for this type of treatment.
- This saved time and effort, but still gave a reliable treatment.
- The Postural Video was helpful in positioning the patient.

Region Örebro County
Örebro University Hospital

Special cases where SGRT is extra helpful

Case 3:

86 year old male

Diagnosis: Skin cancer, metastases on the neck.

Prescribed dose: 7 Gy x 3. Palliative intent.

Treated 231220 – 240103.

The patient has given written consent to presentation of images from the treatment.

Region Örebro County
Örebro University Hospital

Case 3 Anatomy

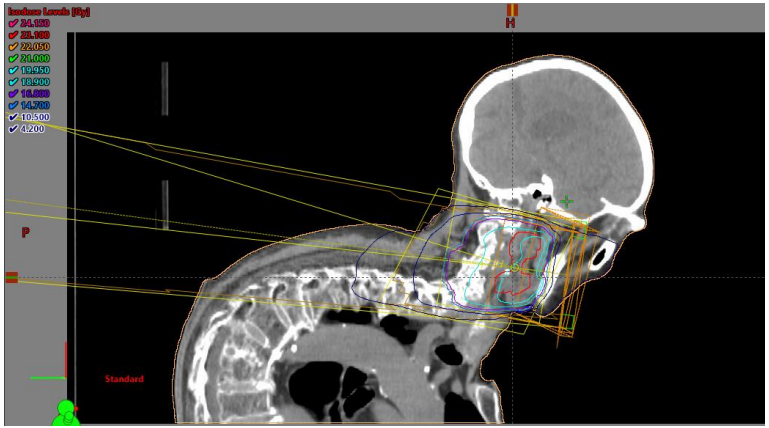

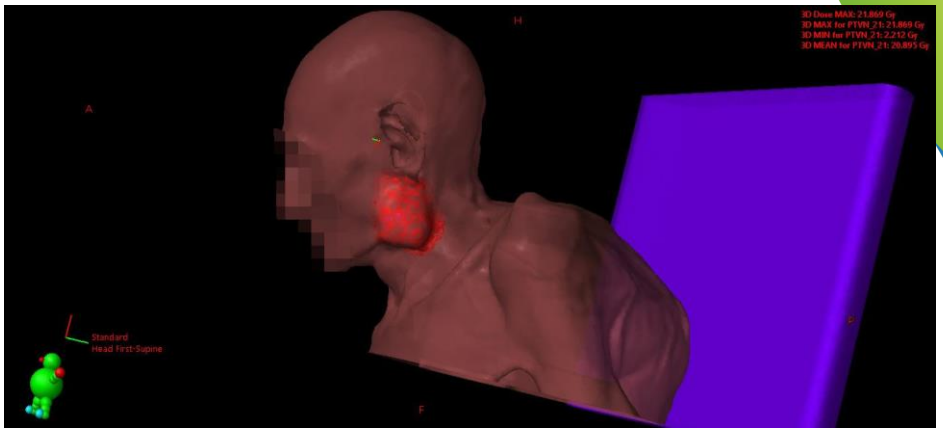

Similar anatomy to case 1, but different treatment intent.

Region Örebro County
Örebro University Hospital

Case 3 Treatment setup

Using experience from case 1, we recently treated a case with similar anatomy to case 1 but in a palliative intent. The vacuum bag was designed to better support the head, neck and shoulders.

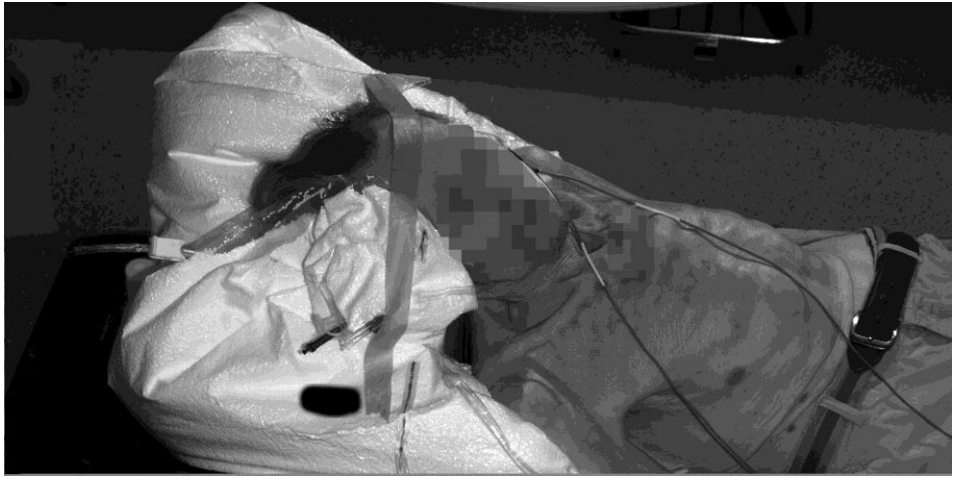

Region Örebro County
Örebro University Hospital

Case 3 Treatment plan

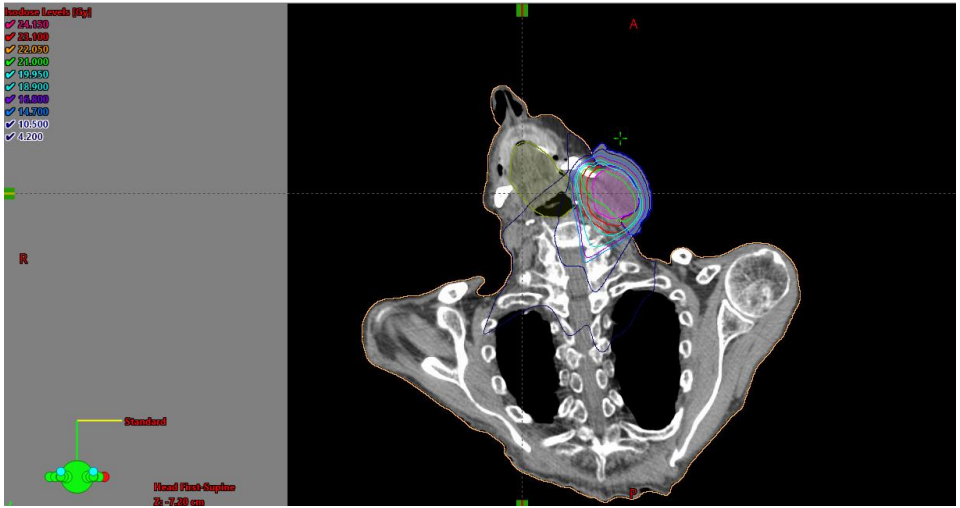

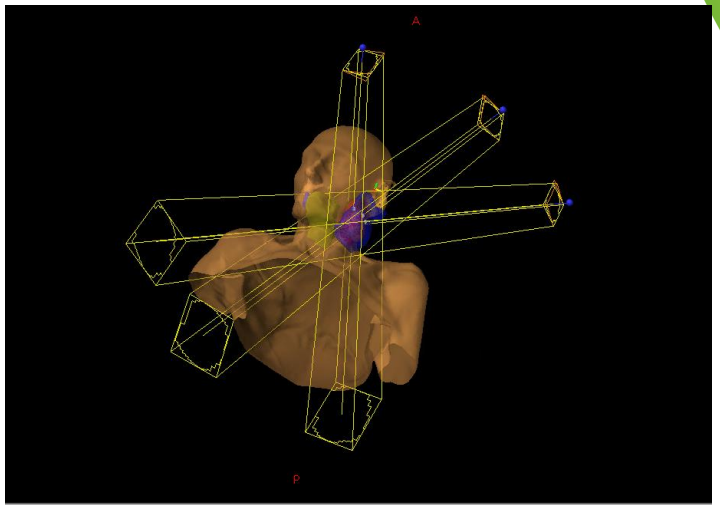

Fixed field treatment plan with 3 conventional fields.

Case 3 Conclusions

- We were able to treat a very old patient with multiple other diseases with good patient comfort despite a difficult anatomy.
- The Postural Video was the primary tool for positioning the patient.
- Motion monitoring gave confidence in treating with high fraction doses.

Region Örebro County
Örebro University Hospital

Thank you for your attention!

My thanks to Jessica Waldesjö for helping with the presentation and acquiring patient consent.