


REACHING NEW
HEIGHTS WITH
SGRT



Maskless Head & Neck Treatments

Danae McCarthy, RT(T)
Cleveland Clinic Cancer Center



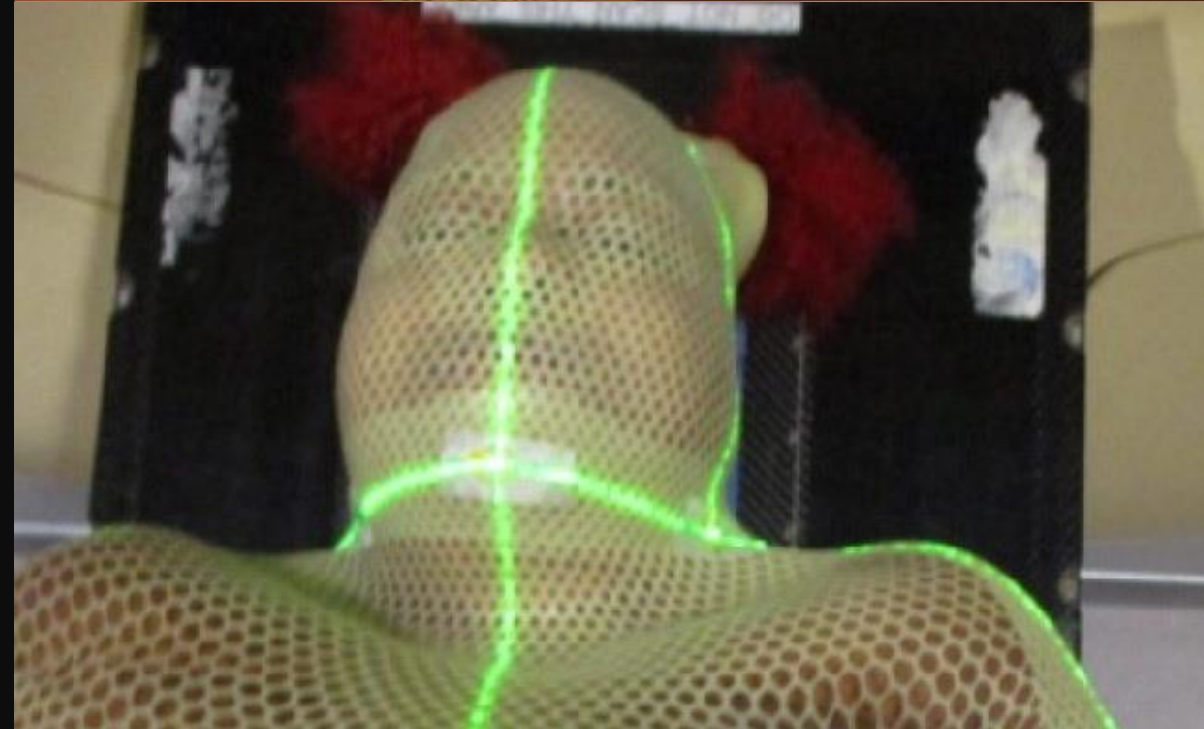
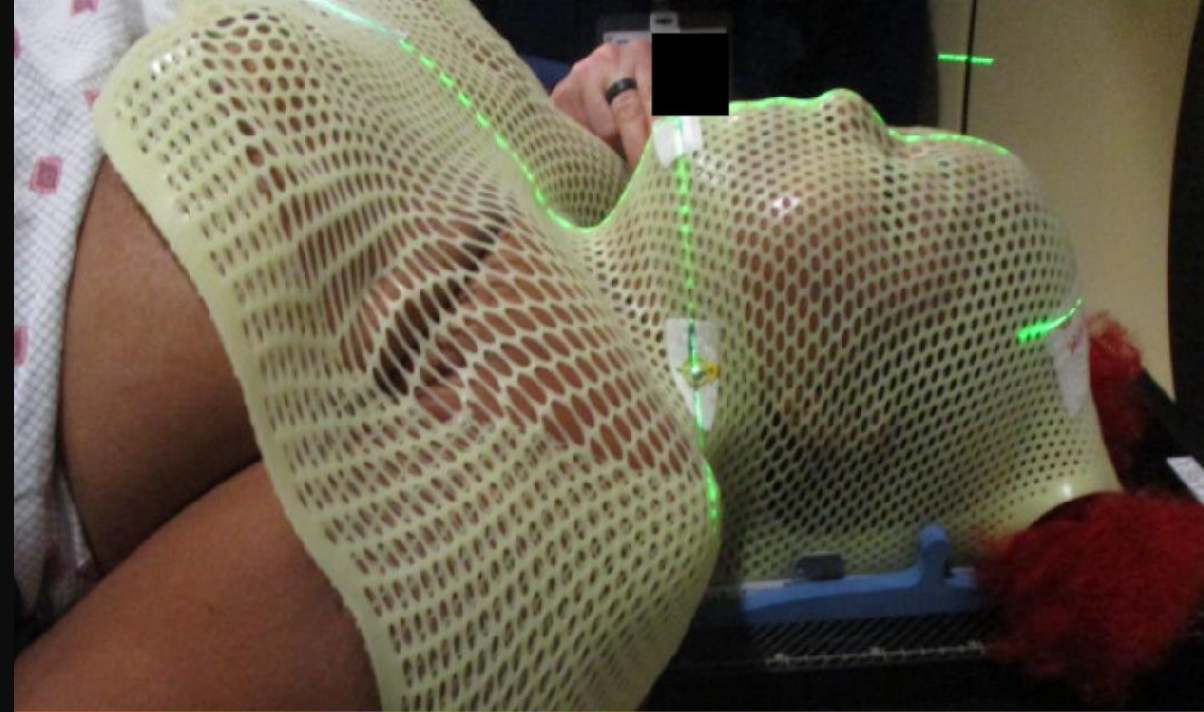
Maskless Surface Guided Radiation Therapy for head and neck treatment.

Danae McCarthy RTT (R)(T)

Cleveland Clinic Taussig Cancer Center

TYPICAL HEAD & NECK MASK TREATMENT

- 5 POINT THERMOPLASTIC MASKS:
 - PATIENT MARKS
 - HARD BOLUS
 - IMMOBILIZES PATIENT
-



POSSIBLE
PROBLEMS
USING A
MASK FOR
TREATMENT

CLAUSTROPHOBIA

1/3-1/2 NEED ATATIVAN

TIGHTENS AFTER SIMULATION

PAINFUL

BLEEDING WHEN REMOVING MASK

LESIONS

CUT MASKS DUE TO SWELLING

BOLUS NOT STAYING IN PLACE

PROMISE OF SGRT

3D SURFACE IMAGING USED
FOR PATIENT POSITIONING
AS WELL AS TRACKING THE
PATIENT WHILE ON
TREATMENT.

- REDUCTION IN TREATMENT TIME
- LESS EXPOSURE (MULTIPLE CBCT'S)
- ELIMINATES WASTES (MASKS)
- ENHANCES SAFETY
- IMPROVED ACCURACY

In 2015 Cleveland Clinic experienced using AlignRT as a standard for all breast patients then extremities and pelvic patients.

Maskless Head & Neck started out as a necessity....



47 yo healthy women mid larynx treatment experiencing panic attacks, refused treatment, failed Ativan then switched to maskless treatment using only CBCT in Jan 2022 for remaining 7 fractions. Treatment went well and she is cured.

Doctors at the Cleveland Clinic decided to expand this type of treatment by adding moldcare on top of a head pad at simulation and Vision RT.

The Clinic treated 5 total patients, 9 total sessions, all did great!



PROCESS:

moldcare

tape forehead



use vision

set tolerance 3mm IMRT and 2mm for SBRT

intrafraction monitoring

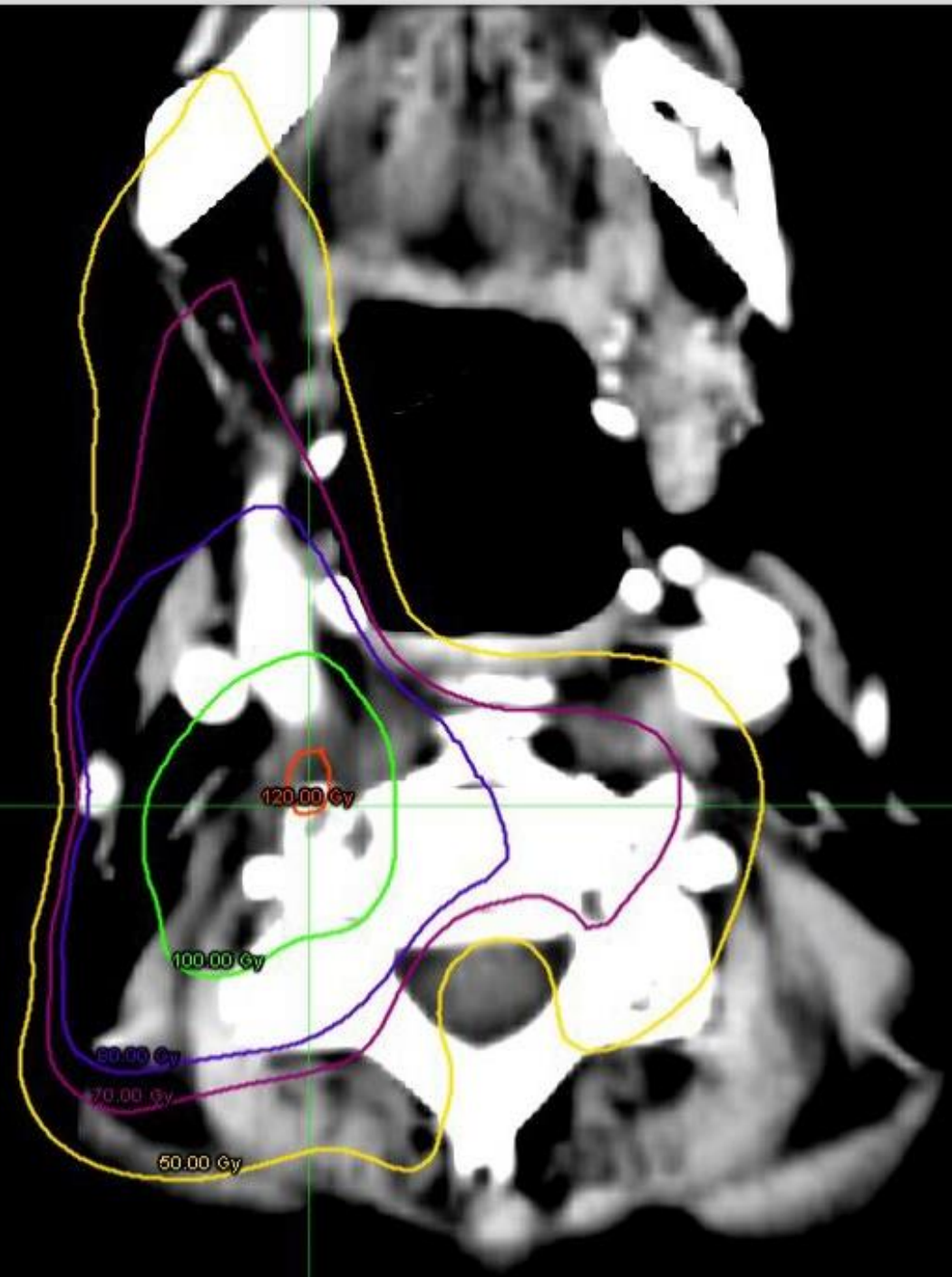
ROI

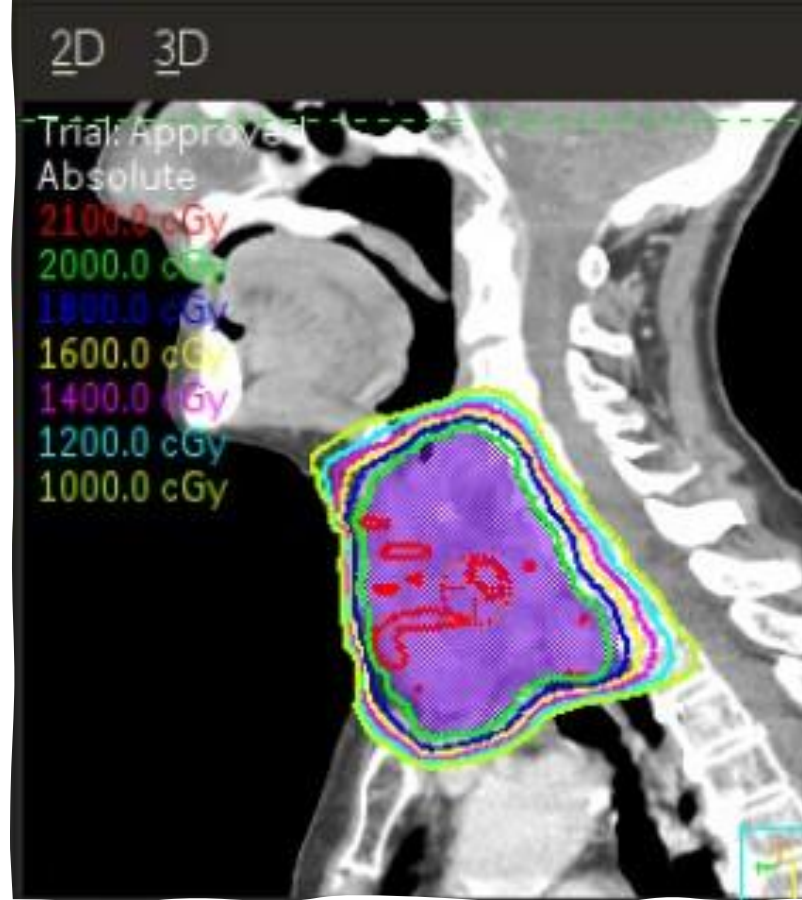

neutral head placement



75 year old patient had skull base salivary gland cancer, refused surgery, extremely anxious refused RT if mask would be used, treated her with 35 fractions maskless Dec 2022, treatment never went out of tolerance. She developed spine mets, treated spine SBRT June 2023 and SBRT reRT Dec 2023, Then treated SBRT to R skull IMRT quad shot Aug 2024. Used Vision for all treatments. She continues to do well.

OUTCOME





Moving towards
machine start
for inpatients

83 yo woman rapidly
progressive
anaplastic thyroid
cancer

Trachea deviated
SOB, in ICU needed
urgent IMRT

Planned for 20gy in 5fx
on diagnostic CT

Plan was for machine
start with shifts using
CBCT and Vision RT
intrafraction motion

Used Vision RT
without a mask

Patient lined up great
and tolerated the
treatment well

Lessons Learned

Maskless treatment works, patients do hold still due to being less anxious, CBCT allows accurate alignment, and vision provides confidence and intrafraction motion is minimal.

Cleveland Clinic is starting a prospective phase II trial using mold care, CBCT setup and Vision RT based maskless RT for H&N cancer treatments used to help create this as our new standard.

REACHING NEW
HEIGHTS WITH
SGRT



To take part in our
event polls, scan here:



... or visit sli.do and enter code
SGRTUSA25